

Chapter 14

Ocular Injuries

Introduction

The preservation of the eyes and eyesight of service personnel is an extremely important goal. Although accepted medical priorities are described as “life, limb, and sight,” most casualties would reprioritize the list as “life, SIGHT, and limb.” Despite comprising as little as 0.1% of the total body surface area, eye injuries accounted for 6%–13% of all combat casualties in Operation Iraqi Freedom/Operation Enduring Freedom. Between 66% and 75% of eye casualties will be medically disqualified from service. In the Vietnam War, almost 50% of casualties with penetrating eye wounds lost the injured eye. The best outcomes are heavily predicated on proper early mitigation and treatment of the injury, as well as prompt transfer to ophthalmic surgical care. Nevertheless, 96% of eye casualties (or more) may be improperly treated at the point of injury. Although improvements in ophthalmic care in the last 30 years offer hope that blindness in combat casualties will be less common in future wars, the eye continues to demonstrate its notorious intolerance of injury—and error—underscoring the critical need for proper initial casualty care.

True Ocular Emergencies

- Chemical injury.
- Open globe.
- Orbital compartment syndrome.
- Acute glaucoma.
- Retinal detachment.

Triage of Patients With Eye Injuries: SHIELD AND SHIP

- Advanced Trauma Life Support protocols: After primary survey is complete and the patient is stable, identify and treat ocular injuries in the secondary survey.

- Casualties with minor eye injuries may be treated and returned to duty.
- Casualties with more severe injuries should be urgently evacuated to the nearest ophthalmic facility within 12 hours to save vision.
- Distinguishing serious ocular injuries from minor ones may be difficult; maintain a high index of suspicion and err on the side of major injury, especially if any part of the eyes/lids that would otherwise be protected by eye protection is involved.
- At Roles 1 and 2, due to time, equipment, and capability constraints, medical personnel should simply document vision, administer systemic antibiotics, and “shield and ship” the patient to the nearest ophthalmologist. If an open globe is suspected, protect the eye with a rigid shield that vaults the eye cleanly and distributes forces to the bony orbit and away from the eye, and evacuate the casualty emergently. DO NOT apply pressure to the eye, patch it, or place any dressings under the shield. Commercially made shields are included in modern Individual and Joint First Aid Kits (IFAK/JFAK), Combat Medic Aid Bags, and Combat Lifesaver Kits, but simply replacing ballistic eye armor (even if moderately damaged) will effectively protect the eye from additional trauma. Metal shields can be molded like splints to accommodate eyelid and orbital swelling.
- Ensure an eye shield is in place and maintained at every echelon of care.

Identifying Severe Eye Injuries

- Associated injuries.
 - Fragmentation wounds of the face—think open globe and intraocular foreign body, especially if any part of the eye/eyelid is injured that would otherwise be covered by eye armor.
 - Lid laceration—open the eyelids (gently) and check for underlying globe laceration.
- Vision.
 - Use book print; uniform insignia, lettering and icons; medication labels; finger counting; etc., to evaluate vision.
 - Compare sight in the injured eye to the uninjured eye.

- Severe vision loss (20/200 or worse) is a strong indicator of serious injury and evacuation urgency.
- However, good vision does not rule out serious injury.
- Eyeball structure.
 - Obvious corneal or scleral lacerations.
 - Subconjunctival hemorrhage (SCH), hemorrhagic chemosis—may overlie an open globe.
 - Dark uveal tissue presenting on the surface of the eye indicates an open globe.
 - Foreign body—did it penetrate the eye?
 - Blood in the anterior chamber (hyphema) indicates severe blunt trauma or penetrating trauma.
- Proptosis (protrusion of the eye), particularly tense proptosis—may indicate a retrobulbar hemorrhage and orbital compartment syndrome, which is an ocular emergency.
- Pupils.
 - Pupillary peaking or distortion—may be associated with an open globe; peaked pupil points to the laceration.
 - Unequal size or reactivity, whether constricted or dilated.
- Motility.
 - Decreased motility on one side may be caused by an open globe.
 - Other causes include muscle injury, orbital fracture, and orbital hemorrhage.

Open Globe

- May result from penetrating or blunt eye trauma.
- **May cause loss of vision from either disruption of ocular structures or secondary infection (endophthalmitis).**
- Biplanar radiographs or a CT scan of the orbit may help to identify a distorted eye or a metallic intraocular fragment in a casualty with severe vision loss, a traumatic hyphema, a large SCH, or other signs suspicious for an open globe with an intraocular foreign body. Fine orbit cuts at every 1 to 1.5 mm are required to properly view the globe. Routine “head” protocol 4-mm CT cuts may miss a high number of globe injuries or foreign bodies.
- Open globes **MUST** be evacuated to the nearest ophthalmologist for proper repair. Non-ophthalmologists must not attempt to repair an open globe, even “to stabilize for transport.”

Immediate Treatment of an Open Globe: SHEILD AND SHIP

- Perform a rapid field test of visual acuity.
- Tape a rigid eye shield (NOT a pressure patch) over the eye. Do not put any dressings/gauze/patches under the shield.
- Do not apply pressure on or manipulate the eye, including ultrasound.
- Start systemic quinolone antibiotic PO or IV (eg, moxifloxacin or levofloxacin 500 mg qd).
- Administer tetanus toxoid if indicated.
- Prevent nausea and emesis (ondansetron [Zofran]).
- Administer analgesics as needed. Analgesic doses of ketamine are not contraindicated.
- Do not apply any topical medications.
- Can close opposite eye to limit motion of injured eye.
- Arrange urgent (within 8–12 hours) referral to an ophthalmologist with surgical capabilities.
- Maintain eye shield at every echelon of care.

Treatment of Other Anterior Segment Injuries

Subconjunctival Hemorrhage

- Small SCHs may occur spontaneously or in association with blunt trauma. These lesions require no treatment.
- Bullous SCHs may occur in association with a rupture of the underlying sclera.
- Warning signs for an open globe include a large SCH with chemosis (conjunctiva bulging away from the globe) in the setting of blunt trauma, or **any** SCH in the setting of penetrating injury.
- Casualties with blast injury and normal vision may not require immediate care but may still harbor significant injury that will be unmasked later.
- Suspected open globe patients should be treated as described previously.

Treatment of Chemical Injuries of the Cornea

- Begin copious and continuous irrigation immediately. Do not delay for eye examination.
- Nonsterile water may be used if it is the only liquid available.

- Use topical anesthesia and lid speculum before irrigating, if available (tetracaine or proparacaine ophthalmic); however, do not delay.
- Remove any retained particles. Examine and sweep conjunctival fornices and under the lids.
- Measure the pH of tears to ensure that, if there is either acid or alkali in the eye, irrigation continues until the pH returns to normal. Do not use alkaline solutions to neutralize acidity or vice versa.
- Using the fluorescein test, look for epithelial defect (ie, corneal abrasions):
 - If none, then mild chemical injuries or foreign bodies may be treated with artificial tears and lubricating ointments.
 - If an epithelial defect is present, use a broad-spectrum antibiotic ophthalmic ointment (bacitracin/polymyxin [Polysporin]), erythromycin, or bacitracin) 4 times per day.
- Noncaustic chemical injuries usually resolve without sequelae.
- More severe chemical injuries require prompt ophthalmological evaluation.
- Monitor (daily topical fluorescein evaluation) for a corneal ulcer until epithelial healing is complete.
- Severe acid or alkali injuries of the eye (recognized by pronounced chemosis, limbal blanching, and/or corneal opacification) can lead to infection of the cornea, glaucoma, and possible loss of the eye. Refer to an ophthalmologist urgently, within 12 hours (SHIELD AND SHIP).
- Treat mustard eye injuries with bland ophthalmic ointments, such as 5% boric acid ointment (if available), to provide lubrication and minimal antibacterial effects. Apply sterile petrolatum jelly (if available) between the eyelids to provide additional lubrication and prevent sealing of the eyelids.
- Treat nerve agent ocular symptoms with 1% atropine sulfate ophthalmic ointment (if available); repeat as needed at intervals of several hours for 1–3 days.

Corneal Abrasions

- **Diagnosis.**
 - Be alert for the possibility of an associated open globe, or if a consequence of blast, significant internal blunt ocular trauma.

- The eye is usually very symptomatic, with pain, tearing, and photophobia.
- Vision may be diminished from the abrasion itself or from the profuse tearing.
- Diagnose with topical fluorescein and cobalt blue light (Wood's lamp). Fluorescein that washes away in a rivulet indicates an open and leaking globe (Seidel sign)—treat appropriately.
- A topical anesthetic as above may be used for diagnosis, but should NOT be used as an ongoing analgesic agent—this delays healing and may cause other complications.
- Treatment.
 - Apply broad-spectrum antibiotic ointment (bacitracin/polymyxin [Polysporin], erythromycin, or Bacitracin) qid.
 - Options for pain relief:
 - ◆ Diclofenac: 0.1% drops qid.
 - ◆ Larger abrasions may require a mild cycloplegic agent (1% tropicamide [Mydracyl] or cyclopentolate [Cyclogyl]).
 - ◆ More severe discomfort can be treated with homatropine or 0.25% scopolamine 1 drop bid, but this will result in pupil dilation and blurred vision for 5–6 days.
 - Small abrasions usually heal well.
 - If the eye is not shielded:
 - ◆ Antibiotic drops (fluoroquinolone or aminoglycoside) may be used qid instead of ointment.
 - ◆ Sunglasses are helpful in reducing photophobia.
 - Ask about contact lens wear. Be aware that troops will wear contact lenses in the field even though they are prohibited. Contact lens-associated corneal abrasions may quickly develop into corneal ulcers, which require aggressive and intense antibiotic treatment and often require evacuation to ophthalmology/optometry.
 - Abrasions will normally heal in 1–4 days.
 - Initial treatment of thermal burns of the cornea is similar to that for corneal abrasions.
 - White phosphorous exposures (flares, pyrotechnics, tracer rounds, etc) must be treated under fluid (water, ointment) because the chemical ignites on air contact and can cause devastating burns.

All corneal abrasions need to be checked once a day until healing is complete to ensure that the abrasion has not been complicated by secondary infection (corneal ulcer, bacterial keratitis).

Corneal Ulcer and Bacterial Keratitis

- Diagnosis.
 - **Corneal ulcer and bacterial keratitis are serious conditions that may cause loss of vision or even loss of the eye!**
 - A history of corneal abrasion or contact lens wear.
 - Increasing pain and redness.
 - Decreasing vision.
 - Persistent or increasing epithelial defect (positive fluorescein test).
 - White or gray spot on the cornea seen on examination with a penlight or direct ophthalmoscope.
- Treatment.
 - Quinolone drops (eg, ofloxacin [Ocuflox]), 1 drop every 5 minutes for 5 doses initially, then 1 drop every 30 minutes for 6 hours, and then 1 drop hourly around the clock thereafter.
 - Scopolamine 0.25%, 1 drop bid, may help relieve discomfort caused by ciliary spasm.
 - Patching and use of topical anesthetics for pain control are contraindicated (see pain control measures discussed previously).
 - Expedited referral to an ophthalmologist within 3–5 days, sooner if condition is deteriorating (decreasing vision, increasing pain/redness, hypopion). Infection may worsen, leading to permanent injury.

Conjunctival and Corneal Foreign Bodies

- Diagnosis.
 - Abrupt onset of discomfort and/or history of suspected foreign body.
 - If an open globe is suspected, treat as discussed previously.
 - Definitive diagnosis requires visualization of the offending object, which may sometimes be quite difficult.

- ◆ A hand-held magnifying lens or pair of reading glasses will provide magnification to aid in the visualization of the foreign body.
- ◆ Stain the eye with fluorescein to check for a corneal abrasion.
- The casualty may be able to help with localization if asked to indicate the perceived location of the foreign body prior to instillation of topical anesthesia.
- Eyelid eversion with a cotton-tipped applicator helps the examiner identify foreign bodies located on the upper tarsal plate.
- Treatment.
 - Superficial conjunctival or corneal foreign bodies may be irrigated away or removed with a moistened sterile swab under topical anesthesia.
 - Objects adherent to the cornea may be removed with a swab or a sterile 22-gauge hypodermic needle mounted on a tuberculin syringe (hold the needle **tangential** to the eye).
 - If no foreign body is visualized, but the index of suspicion is high, vigorous irrigation with artificial tears or sweeps of the conjunctival fornices with a moistened cotton-tipped applicator after topical anesthesia may be successful in removing the foreign body.
 - If an epithelial defect is present after removal of the foreign body, treat as discussed previously for a corneal abrasion.

HypHEMA: Blood in the Anterior Chamber

- Can occur after blunt or penetrating trauma and significant intraocular injury. SHIELD AND SHIP.
- Treatment (to prevent vision loss from increased intraocular pressure):
 - Be alert for a possible open globe and treat for that condition if suspected.
 - Avoidance of rebleeds is a major goal of management.
 - ◆ **Avoid** aspirin and nonsteroidal antiinflammatory drugs.
 - ◆ If a polytrauma patient must be systemically anticoagulated (eg, enoxaparin), monitor eye status for expansion of hypHEMA or rebleed.

- ◆ No strenuous activity (bedrest with head of bed elevated) for 7 days.
- ◆ No reading for 7 days to minimize rapid eye movements.
- Prednisolone 1%—1 drop 4 times a day.
- Scopolamine 0.25%—1 drop twice a day.
- Cover eye with protective shield.
- Elevate head of bed to promote settling of red blood cells in anterior chamber.
- Provide a 24- to 48-hour referral to an ophthalmologist to monitor for increased intraocular pressure (which may cause permanent injury to the optic nerve) and to evaluate for associated intraocular injury.
- If evaluation by an ophthalmologist is delayed (>24 hours), treat with a topical beta-blocker (timolol or levobunolol) bid to help prevent intraocular pressure elevation.
- If intraocular pressure is found to be markedly elevated (above 30 mm Hg) with a tonometry device (eg, Tonopen), other options for lowering intraocular pressure include acetazolamide (Diamox) 500 mg PO or IV and mannitol 1–2 g/kg IV over 45 minutes.

Orbital Compartment Syndrome (Retrobulbar Hemorrhage)

- A clinical diagnosis. This is a true ocular emergency in which minutes matter and that cannot wait on diagnostic imaging or transfer to an ophthalmologist.
- Retrobulbar hemorrhage most often occurs after blunt or penetrating orbital trauma, but there are other etiologies.
- Keys to recognition: Severe eye pain, tense proptosis (“rock hard” orbit), vision loss, afferent pupillary defect, and decreased eye movement.
 - Marked lid edema may make the proptosis difficult to appreciate. Inability to open the lids, even with cotton swabs, is highly suspicious for this.
 - Failure to recognize the condition may result in blindness within 60–90 minutes from increased ocular/orbital pressure and ischemia.
- Perform an immediate lateral canthotomy and cantholysis.
- Provide an urgent referral to an ophthalmologist, within 24–48 hours (SHIELD AND SHIP).

- If evaluation by an ophthalmologist is delayed (>24 hours), treat with a topical beta-blocker (timolol) bid to help lower intraocular pressure elevation.
- If intraocular pressure remains elevated (>30 mm Hg), treat as discussed previously, including acetazolamide, mannitol, or hypertonic saline to decrease intraorbital pressure.

Lateral Canthotomy/Cantholysis

The indication for lateral canthotomy/cantholysis is orbital compartment syndrome. It is not an easy procedure to do properly in the face of marked orbital distention and tight tissues. Do not perform such procedures if the eyeball structure has been violated. If there is a penetrating globe injury, apply a rigid eye shield for protection and seek immediate ophthalmic surgical support (SHIELD AND SHIP).

- Inject 2% lidocaine with 1:100,000 epinephrine into the lateral canthus (Fig. 14-1a).
- Crush the lateral canthus with a straight hemostat, advancing the jaws to the lateral fornix and bony orbital rim (Fig. 14-1b).
- Using straight blunt-tipped scissors, make a 1-cm horizontal incision of the lateral canthal tendon (canthotomy) in the middle of the crush mark (Fig. 14-1c). Incision should extend to the bony lateral orbital rim.
- Grasp the lower eyelid with large toothed forceps (eg, Adson), pulling the eyelid vertically away from the face, toward the ceiling. This pulls the inferior crus (band of the lateral canthal tendon) tight so it can be easily cut loose from the orbital rim (Fig. 14-1d). It will have a “banjo string” feel against the tip of the scissors.
 - Use blunt-tipped scissors to cut the inferior crus.
 - Keep the scissors parallel (flat) to the face with the tips pointing toward the corner of the mouth or nasal ala.
 - Make a FULL THICKNESS cut across the lower lateral lid, incorporating the conjunctiva and skin (cantholysis).
 - The eyelid should swing freely away from the rim, detaching like a hammock, thereby relieving pressure on the globe. (Fig. 14-1e)
 - Cut residual lateral attachments of the lower eyelid if it does not move freely. (Strum with scissors tips, feeling for restricting tethers; incise any residual bands)

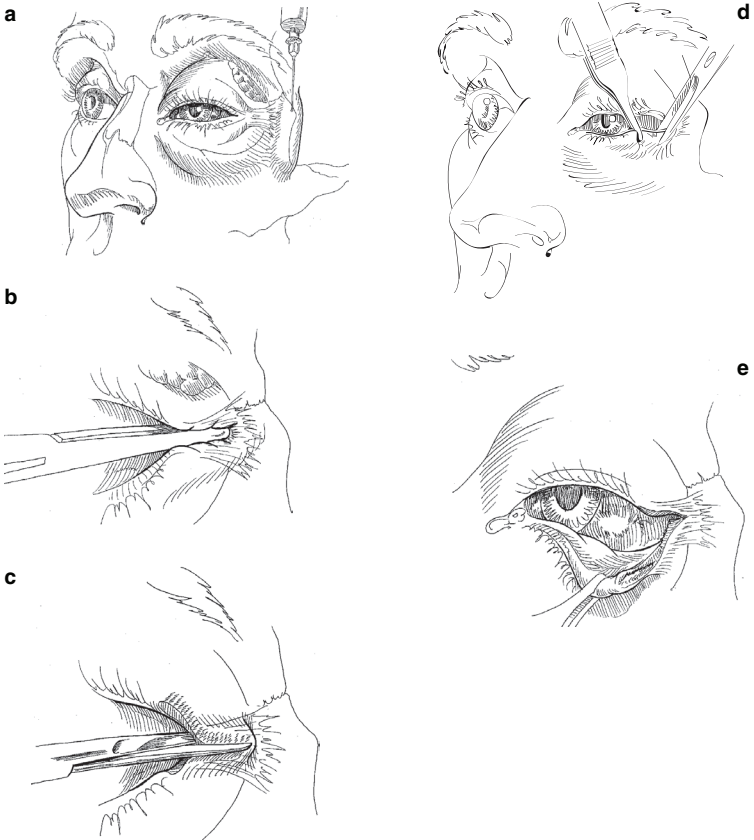


Fig. 14-1. Lateral canthotomy and inferior cantholysis are indicated for casualties presenting with serious orbital hemorrhage.

- Do not worry about the cosmetics of cutting 1 cm of conjunctiva or skin.
- The lower eyelid is cut, relieving orbital pressure. If the intact cornea is exposed, apply, hourly, copious erythromycin ophthalmic ointment or ophthalmic lubricant ointment to prevent devastating corneal desiccation and infection. Relief of orbital pressure must be followed by lubricating protection of the cornea and urgent ophthalmic surgical support. Do NOT apply absorbent gauze dressings to the exposed cornea.

- Continue to monitor vision throughout evacuation.

Orbital Floor (Blowout) Fractures

These fractures are usually the result of a blunt injury to the globe or orbital rim, often associated with head and spine injuries. Blowout fractures may be suspected on the basis of enophthalmos (sunken eye), diplopia, decreased ocular motility, hypoesthesia of the V2 branch of the trigeminal nerve, associated SCH, or hyphema.

- Presence of an afferent pupillary defect (or Marcus Gunn pupil), in which light shone into the affected eye causes less pupillary constriction than the consensual reflex when light is shone into the unaffected eye, may represent bony optic nerve impingement and is an indication for immediate orbital exploration and repair if fractures are present.
- If severe impingement of upward gaze is present, especially when accompanied by bradycardia or nausea/vomiting (oculocardiac reflex), impingement of an extraocular muscle should be presumed and the orbit should be explored urgently, ideally within 1 hour.
- Immediate treatment includes pseudoephedrine 60 mg q6h and a broad-spectrum antibiotic for 7 days, ice packs, and instructing the casualty not to blow their nose.
- Definitive diagnosis requires CT scan of orbits with axial and coronal views.
- Indications for non-urgent repair include severe enophthalmos and diplopia in the primary or reading gaze positions.
- If conditions described above are not present, this condition is not an urgent matter; surgery may be performed 1–2 weeks after the injury.

Lid Lacerations

Treatment Guidelines for Lid Lacerations Not Involving the Lid Margin

- Excellent blood supply—delayed primary closure is not necessary. Do not excise or sharply debride tissue.
- Eyelid function (protecting the globe) is the primary consideration.

- Begin with irrigation, cleansing debridement, and antisepsis (any topical solution, but no detergent or chlorhexidine-based products—eg, povidone iodine soap [Betadine Scrub, Hibiclens]), and check for retained foreign bodies.
- Superficial lacerations of the eyelid not involving the eyelid margin may be closed with running or interrupted 6-0 silk or monofilament.
- Visible orbital fat, by definition, indicates a deeper orbital injury requiring more sophisticated evaluation and treatment—SHIELD AND SHIP.
- Horizontal laceration closure should include the superficial orbicularis muscle and skin. Avoid layered closures.
- If skin is missing, an advancement flap may be created to fill in the defect, but preferably, defer flap creation to ophthalmology. For vertical or stellate lacerations, use traction sutures in the eyelid margin for 7–10 days.
- Antibiotic ointments qid.
- Skin sutures may be removed in 5 days.

Laser Eye Injuries

- Battlefield lasers may be designed to cause eye injuries or may be part of other weapons or sensor systems.
- **Prevention is the best option!** Wear eye protection designed for the appropriate light wavelengths if there is a known laser threat.
- The type of ocular damage depends on the wavelength and power of the laser. Retinal injuries are most common.
- The primary symptom of laser injury is loss of vision, which may be preceded by seeing a flash of light. Pain may not be present.
- Immediate treatment of corneal laser burns is similar to that for corneal abrasions.
- Laser retinal burns have no proven immediate treatment, although improvement with corticosteroids and nonsteroidal antiinflammatories has been reported.
- Routine evacuation for evaluation by an ophthalmologist is required.

Enucleation

Because there is no method to restore vision, the decision to remove an eye is not to be taken lightly. The following recommendations apply to treatment of friendly and coalition forces, understanding that exigencies of combat may dictate providing care to host nationals or local populations who cannot be treated by more sophisticated echelons.

A general surgeon in a forward unit should not remove a traumatized eye, and under no circumstances should a bilateral primary enucleation be performed by anyone other than an ophthalmologist. Primary enucleation should only be considered if the patient has a devastatingly severe injury with non-salvageable disorganization, no light perception using the brightest light source available, or early endophthalmitis. Because of new surgical technologies and methods—and because there is no going back on the decision to enucleate—the ophthalmologist is the best judge of determining such hopelessness. Sympathetic ophthalmia is a condition that may result in loss of vision in the fellow eye if a severely traumatized, nonseeing eye is not removed; however, it rarely develops prior to 21 days after an injury. **Thus, delaying enucleation until the patient is in the care of an ophthalmologist is relatively safe.**

**For Clinical Practice Guidelines, go to
http://jts.amedd.army.mil/index.cfm/PI_CPGs/cpgs**